

## MORPHOLOGICAL CHANGES IN THE NERVE GLODS OF THE SOLAR PLEXUS AFTER CHOLECYSTECTOMY IN DOGS

**Rakhmonova Khabiba Nurullaevna, Rakhmonov Zafarzhon Mamadievich**

Assistants teachers Departments of “Histology, cytology and embryology” and “Human anatomy”, Samarkand State Medical University, Samarkand, Uzbekistan

<https://doi.org/10.5281/zenodo.8057126>

**Abstract:** The ganglia of the celiac (solar) plexus, as the most important peripheral autonomic centers, play a significant role in the innervation of the abdominal organs. Of the extramural autonomic ganglia, they turned out to be the least studied. In the morphological literature, there are single works devoted to the microstructure and connections of the ganglia of the celiac plexus. Therefore, most of the most important questions on the efferent and afferent innervation of the celiac ganglia, the connection of the latter with the central nervous system and the organs of the gastrointestinal tract are still far from being resolved. Consequently, the intramural nervous apparatus of the gallbladder is represented by nerve nodes of various sizes, which are located at the intersection of bundles of nerve fibers. All three types of Dogel's nerve cells were found in the composition of the nodes. The largest nodes are located in the neck of the gallbladder. Gallbladder neurons are relatively autonomous, bile secretion is controlled by the vagus nerves and modulated by peptide hormones.

**Keywords:** celiac plexus, ganglia, neurons, synapses, experimental cholecystectomy.

## МОРФОЛОГИЧЕСКИЕ ИЗМЕНЕНИЯ В НЕРВНЫХ УЗЛАХ СОЛНЕЧНОГО СПЛЕТЕНИЯ ПОСЛЕ ХОЛЕЦИСТЭКТОМИИ У СОБАК

**Аннотация:** Ганглии чревного (солнечного) сплетения, как важнейшие периферические вегетативные центры, играют значительную роль в иннервации органов брюшной полости. Из экстрамуральных вегетативных ганглиев они оказались наименее изученными. В морфологической литературе имеются единичные работы, посвященные микростроению и связям ганглиев чревного сплетения. Поэтому большинство важнейших вопросов об эфферентной и афферентной иннервации чревных ганглиев, связи последних с центральной нервной системой и органами желудочно-кишечного тракта еще далеки от разрешения. Следовательно, интрамуральный нервный аппарат желчного пузыря представлен различными по величине нервными узлами, располагающимися в месте пересечения пучков нервных волокон. В составе узлов обнаружены все три типа нервных клеток Догеля. Наиболее крупные узлы расположены в области шейки желчного пузыря. Нейроны желчного пузыря относительно автономны, секреция желчи контролируется блуждающими нервами и модулируется пептидными гормонами.

**Ключевые слова:** чревное сплетение, ганглии, нейроны, синапсы, экспериментальная холецистэктомия.

## INTRODUCTION

In the last decade, both in Uzbekistan and abroad, despite the emergence of new drugs for the correction of functional disorders of the digestive system, there has been no decrease in the number of dysfunctions of the biliary system. When studying the biliary system, it was revealed that it is characterized by the presence of many sphincters from coordinated work, which release bile into the intestine at the time of digestion and into the gallbladder outside the moment of digestion. It has been established that there is a direct innervation connection between them. In addition, the gallbladder has innervation connections with other organs of the abdominal cavity. Therefore, in diseases of the gallbladder, friendly violations of the functions of other organs occur,

and clarification of the nervous mechanism of these friendly reactions is of certain importance [1,2,6]. Small branches of the vagus nerve innervate the common bile duct, as well as the ampulla of Vater's papilla. At the same time, local viscerovisceral reflex interactions between the internal organs of the abdominal cavity are closed in the nodes of the celiac (solar) plexus. This proves that the impact on one of the internal organs causes morphofunctional changes in others [3,4,5]. The gallbladder has innervation connections with almost all organs of the digestive tract. Based on the foregoing, we studied the morphology of the nodes of the celiac plexus of adult dogs in the norm and after experimental cholecystectomy in the early and late periods.

**OBJECTIVE:** to identify the morphofunctional features of the nerve nodes of the celiac plexus after experimental cholecystectomy in dogs.

#### **MATERIALS AND METHODS.**

The nerve nodes of the celiac plexus of 15 dogs (6 of them control) after experimental cholecystectomy served as the material for our studies. It should be noted that in the structure of the ganglia of the celiac plexus of animals, we did not find any difference in terms of sex. The celiac nerve was cut under the diaphragm, at the place of its entry into the corresponding ganglia of the celiac plexus. The material was taken from 12 hours to 12 days after the operation. After unilateral transection of the celiac nerve, in some cases, the right and left celiac ganglia (or their corresponding plexus areas at node fusion) were separately fixed and examined.

Animals are euthanized under anesthesia, strictly observing the rules of bioethics. On the 3rd, 5th and 7th days after the operation, the nodes of the celiac solar plexus were taken immediately after the animals were slaughtered and fixed in 12% neutral formalin. After washing with running water, the material was dehydrated and compacted into paraffin. The preparation of histological preparations was carried out according to the generally accepted method. Paraffin sections were stained according to the Lasky method, and cryostat sections were impregnated with silver nitrate according to the Bilshovsky-Gross and Campos methods.

#### **RESULTS AND DISCUSSION**

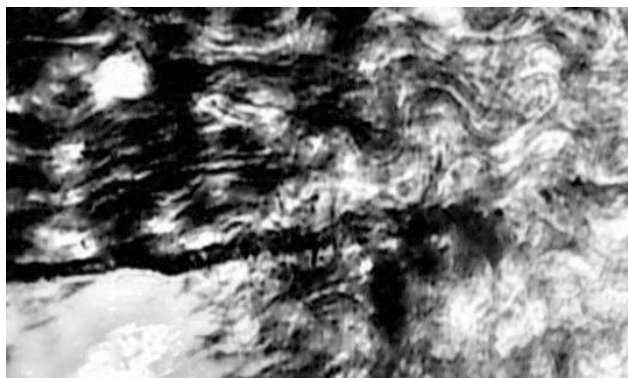
As our studies have shown, the celiac plexus of animals consists mainly of two (rarely three or more) ganglia and many visceral branches. On each side of the celiac artery was a separate, or to some extent fused ganglion. In some cases, accumulations of chromaffin tissue are found inside the celiac ganglia and near their capsule. The celiac ganglia are externally covered with a connective tissue capsule. This shell is expressed to varying degrees - depending on age. A layer of connective tissue capsules penetrates the ganglion, dividing the neurons into relatively limited clusters (islets). Some researchers attribute a special role to these islands: they consider them as peripheral centers of any abdominal organ.

The capsule of neurons of the celiac ganglia in animals is weakly expressed. The severity of the capsule of celiac plexus neurons depends on the amount and age of glia, the presence of connective tissue between cells, and, as our studies have shown, on the state of the neuron itself. Under certain unfavorable conditions, as a response to violations of neurohumoral factors, a reaction occurs from the glial and connective tissue elements located around the neuron. The foregoing is confirmed by the fact that in most cases in the experiment and in pathology the capsule of neurons is comparatively better expressed.

The size of the nerve cells of the celiac ganglia ranged from 20-50 microns. Occasionally there were giant neurons, the size of which is 2-3 times larger than the size of adjacent nerve cells. The nerve cells of the celiac ganglia have one nucleus, rarely two or three. The nucleus contains a

variable number of nucleoli. Their shape and size are not the same. The number of nucleoli is usually 2-3, but can be up to 10 or more.

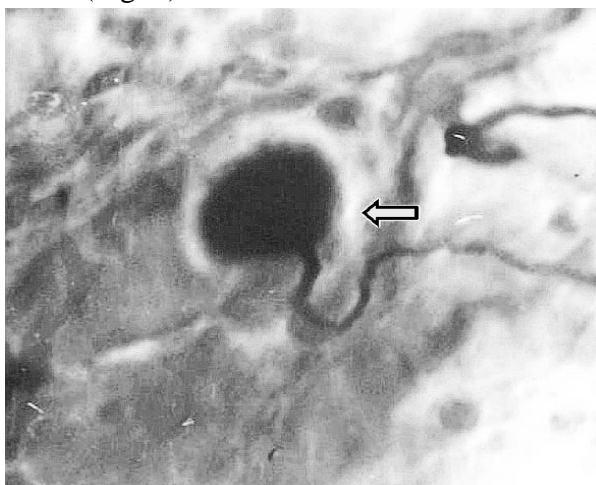
Removal of the gallbladder in all cases is accompanied by changes in the nerve elements. In the early stages (3 days after surgery), changes in nerve fibers and nerve endings come to the fore. In some cases, it is found that some nerve fibers in the bundle have varicose swellings or are fragmented (Fig. 1).



**Fig.1. Hyperimpregnated and hypertrophied nerve fibers in the node of the celiac plexus of the dog. 3 days after the experiment. Impregnation according to the Bilshovsky-Gross method. About. 20, ok. 10.**

In other cases, fragments of already disintegrated nerve fibers and unchanged intact synaptic nerve endings are visible. In some preparations, various stages of degeneration and decay of nerve fibers are noted. In the later periods of observation (5-7 days) after removal of the gallbladder, changes in nerve fibers intensify, more and more late stages of degeneration are encountered, that is, lumpy and granular decay.

The synaptic nerve endings on the neurons of the solar plexus nodes also undergo certain changes. Already on the 3rd day after cholecystectomy, they hypertrophy and acquire an elongated oval shape. The preterminals of these endings are also hyperimpregnated and have small varicose swellings. On the 5th and 7th days of the experiment, in the nodes of the celiac plexus, sharply hypertrophied synaptic endings of an irregularly spherical shape are found, along the edges of which small notches are determined (Fig. 2).



**Fig.2. A sharply enlarged nerve ending at the solar plexus node. 7 days after cholecystectomy. Campos impregnation. Ob.90, ok.10.**

The preterminals of such endings have pronounced varicose swellings and are hyperimpregnated; a sharp expansion of the perifibrillar space is also noted.

We did not find similar changes in the nerve ganglions of the celiac plexus in control animals.

After removal of the gallbladder, certain metabolic changes occur in the nodes of the celiac plexus. If in control animals chromatophilic substance (tigroid substance) in the form of basophilic lumps is detected in all nerve cells, then after experimental cholecystectomy a significant decrease in tigroid substance is observed in some cells. These cells are distinguished by a pale color. The process of focal and total tigrolysis is observed in them. In these cells, when stained with Lasky, clumps of basophilic substance are not visible.

### CONCLUSION

The results of our studies indicate that the experimental removal of the gallbladder is accompanied by certain morphological changes in some structural components of the nerve nodes of the celiac plexus. The severity of these changes depends on the period of observation after the experiment. Apparently, the processes of some neurons of the gallbladder wall reach the nodes of the celiac plexus and form synapses with their neurons. After removal of the gallbladder, they undergo reactive changes in the early stages and degenerative changes in the later stages.

These data once again confirm the position that the nodes of the celiac plexus are those peripheral centers where the reflex arcs of viscerovisceral reflexes are closed, which are the material substrate of functional interactions and concomitant diseases of the abdominal organs. Also, this information will be useful in elucidating the pathogenesis of concomitant diseases of internal organs and in evaluating the results of experimental studies.

### LITERATURES

1. Dekhkanov T.D., Oripov F.S. et al., Features of the structural organization of the ampulla of Vater's papilla in animals with different nutrition patterns // Scientific journal. - 2021. - No. 2 (57), Moscow, pp. 94-96.
2. Karpova Ya.A., Shvedov S.I., Comparative morphology of the celiac and cranial mesenteric nodes of representatives of the canine and hare families // Agrarian Bulletin of the Urals.- 2008.-№12 (54).- P. 66-68.
3. Puzikov A.M., Lychkova A.E., Nervous regulation of biliary motility // Experimental and clinical gastroenterology issue.- 2016.- T.131, No. 7.- P. 62-65.Рахмонов З.М. и др., Морфологические свойства рецепторов желчных путей // Новый день в медицине. - 2022.-6 (44).- С. 195-197.
4. Rakhmonova Habiba Nurullaevna, & Rakhmonov Zafarjon Mamadievich. (2023). Innervation Relationships of the Gallbladder Nerve Apparatus with Spinal and Rheumatic Nerve Ganglia (Literature Review). *Eurasian Medical Research Periodical*, 18, 105–108.
5. Tyuryumin Ya.L., Shanturov V.A., Tyuryumina E.E. The role of the gallbladder (literature review) // Bulletin of the VSNC. – 2011. No. 4(80). - P.347 - 352.
6. Yi SQ, Ohta T, Tsuchida A, Terayama H, Naito M, Li J, Wang HX, Yi N, Tanaka S, Itoh M. Surgical anatomy of innervation of the gallbladder in humans and *Suncus murinus* with special reference to morphological understanding of gallstone formation after gastrectomy. *World J Gastroenterol*. 2007 Apr 14;13(14):2066-71. ниверситета им. ИИ Мечникова 7.1 (2015): 46-52.